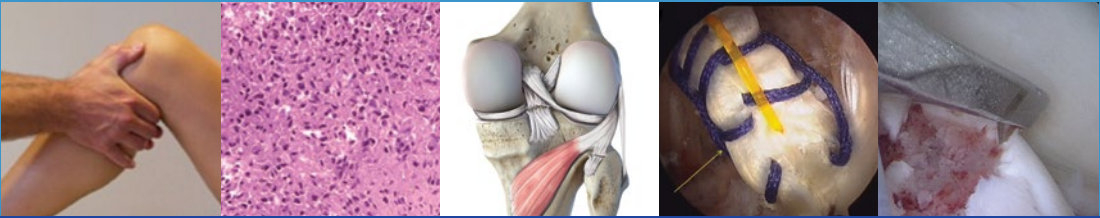


Roland Becker
Gino M.M.J. Kerkhoffs
Pablo E. Gelber
Matteo Denti
Romain Seil *Editors*



ESSKA

Instructional Course Lecture Book Barcelona 2016



ESSKA Instructional Course Lecture Book

Roland Becker • Gino M.M.J. Kerkhoffs
Pablo E. Gelber
Matteo Denti • Romain Seil
Editors

ESSKA Instructional Course Lecture Book

Barcelona 2016

 Springer



Editors

Roland Becker
Chairman
Department of Orthopaedic
and Traumatology
Centre of Joint Replacement
Medical Director of the University
Hospital Brandenburg
"Theodor Fontane Medical School"
Brandenburg/Havel
Germany

Pablo E. Gelber
Hospital de la Santa Creu i Sant Pau
Universitat Autònoma de Barcelona
Barcelona
Spain

Matteo Denti
Istituto Clinico Humanitas
Monza
Italy

Gino M.M.J. Kerkhoffs
Orthopaedic Surgery
Academic Medical Center
AZ Amsterdam
The Netherlands

Romain Seil
Clinique d'Eich
Centre Hospitalier de Luxembourg
Luxembourg

ISBN 978-3-662-49113-3 ISBN 978-3-662-49114-0 (eBook)
DOI 10.1007/978-3-662-49114-0

Library of Congress Control Number: 2016937761

© ESSKA 2016

This work is subject to copyright. All rights are reserved by the Publisher, whether the whole or part of the material is concerned, specifically the rights of translation, reprinting, reuse of illustrations, recitation, broadcasting, reproduction on microfilms or in any other physical way, and transmission or information storage and retrieval, electronic adaptation, computer software, or by similar or dissimilar methodology now known or hereafter developed.

The use of general descriptive names, registered names, trademarks, service marks, etc. in this publication does not imply, even in the absence of a specific statement, that such names are exempt from the relevant protective laws and regulations and therefore free for general use.

The publisher, the authors and the editors are safe to assume that the advice and information in this book are believed to be true and accurate at the date of publication. Neither the publisher nor the authors or the editors give a warranty, express or implied, with respect to the material contained herein or for any errors or omissions that may have been made.

Printed on acid-free paper

This Springer imprint is published by Springer Nature
The registered company is Springer-Verlag GmbH Berlin Heidelberg

Contents

1 Management of PCL Injuries (ICL 1)	1
Fabrizio Margheritini, Robert La Prade, and Sven Scheffler	
2 Biceps Tendinopathy (ICL 2)	11
Boris Poberaj, Ettore Taverna, Carl Dierickx, Pietro Randelli, Chiara Fossati, Anne Karelse, Emilio Lopez-Vidriero, Rosa Lopez-Vidriero, Maximilian Kerschbaum, Mitja Scheuermann, Christian Gerhardt, and Markus Scheibel	
3 Recent Advances in Cartilage Repair (ICL 3)	27
Giuseppe M. Peretti, Peter Angele, Giuseppe Filardo, Elizaveta Kon, Laura Mangiavini, Antongiulio Marmotti, Silvia Mattia, Konrad Slynarski, Francesc Soler, Dieter Van Assche, and Henning Madry	
4 Common Errors in ACL Surgery (ICL 4)	43
Simon Ball, Jonathon Lavelle, Elvire Servien, Urzula Zdanowicz, Joan C. Monllau, and Andy Williams	
5 Stress Fractures in Sport (ICL 5)	53
Nikica Darabos, Mihai Vioreanu, Vladan Stevanovic, Oskar Zupanc, and Umile Giuseppe Longo	
6 Meniscal Root Tears (ICL 6)	65
Nicolas Pujol, Matthias J. Feucht, Christian Stärke, Michael T. Hirschmann, Anna Hirschmann, Alli Gokeler, and Sebastian Kopf	
7 Ankle Instability (ICL 7)	89
Bernard Burgesson, Mark Glazebrook, Stephane Guillo, Kentaro Matsui, Mickey Dalmau Pastor, Fernando Peña, Masato Takao, Jordi Vega, and ESSKA AFAS Ankle Instability Group	

8 Proximal Hamstring Injuries (ICL 8)	101
Anne D. van der Made, Gustaaf Reurink, Lars Engebretsen, Erik Witvrouw, Gino M.M.J. Kerkhoffs, Johannes L. Tol, Sakari Orava, and Håvard Moksnes	
9 Posterolateral Corner Reconstruction: Approach to Treatment Including Mini-open and Arthroscopic Techniques (ICL 10)	113
Ivan Saenz, Xavier Pelfort, Robert F. LaPrade, Brett A. Fritsch, Pablo E. Gelber, and Karl-Heinz Frosch	
10 How to Identify the Optimal Surgical Intervention for Your Osteoarthritic Patient (ICL 11)	127
Michael T. Hirschmann, Nanne Kort, and Roland Becker	
11 Update in Labral Treatment of the Hip (ICL 12)	133
Christoph Lampert, Marc Tey, Hatem Galal Said, Bent Lund, Michael Dienst, and Ernest Schidlers	
12 Evaluation and Surgical Decision-Making in Elbow Instability (ICL 13)	137
Michel P.J. van den Bekerom, Luigi A. Pederzini, Luke Oh, A. Mehmet Demirtaş, Roger P. van Riet, and Marc R. Safran	
13 Peroneal Tendon Disorders (ICL 14)	143
Pim A.D. van Dijk, Youichi Yasui, Chris D. Murawski, C.W. DiGiovanni, P. D’Hooghe, John G. Kennedy, and Gino M.M.J. Kerkhoffs	
14 Posterior Shoulder Instability (ICL 15)	155
Roman Brzóška, Wojciech Solecki, Julien Deranlot, Philipp Moroder, Frank Martetschläger, Maristella F. Saccomanno, and Giuseppe Milano	
15 Posterior Compartment of the Ankle Joint: A Focus on Arthroscopic Treatment (ICL 17)	167
Daniel Haverkamp, Niels Bech, Peter de Leeuw, Pieter d’Hooghe, Akos Kynsburg, James Calder, Tahir Ogut, Jorge Batista, and Hélder Pereira	
16 Bony Defects in Revision ACL Surgery (ICL 19)	185
Julian A. Feller, Andy Williams, Karl Eriksson, and Rainer Siebold	
17 Elbow Arthroscopy: From Basic to Advance (ICL 20)	195
A. Van Tongel, Paolo Arrigoni, Marc R. Safran, Denise Eygendaal, L.A. Pederzini, E. Tripoli, A. Cheli, A. Mehmet Demirtaş, M. Derviş Güner, and Roger P. van Riet	

18 Complications in Rotator Cuff Treatment (ICL 21) 209
Wolfgang Nebelung, Bruno Toussaint, Eduard Buess,
Karsten Labs, Leo Pauzenberger,
and Philipp R. Heuberger

**19 Clinical Utility of Diagnostic Ultrasound
in Athletes with Tendinopathy (ICL 22)** 217
Ferran Abat, Nicola Maffulli, H. Alfredson,
E. Lopez-Vidriero, C. Myers, S. Gomes, and O. Chan

20 How to Make a Video (ICL 23) 225
Nicolas Graveleau, Katja Tecklenburg, David Putzer,
Abdou Sbihi, and Daniel Smith

Index 231

Contributors

Ferran Abat, MD Sports Orthopaedic Department, ReSport Clinic
Barcelona, Barcelona, Spain

H. Alfredson, MD Sports Medicine Unit, University of Umeå,
Umeå, Sweden

Peter Angele, MD, Prof Department of Trauma Surgery, University
Medical Center Regensburg, Regensburg, Germany

Paolo Arrigoni, MD Department of Orthopedics and Traumatology,
University of Milano, Milano, Italy

Simon Ball, MA, FRCS, (Tr&Orth) Chelsea and Westminster Hospital,
and Fortius Clinic, London, UK

Jorge Batista, MD Clinical Department Club Atletico Boca Juniores,
CAJB – Centro Artroscopico, Buenos Aires, Argentina

Niels Bech SCORE (Slotervaart Center of Orthopedic Research
and Education), Amsterdam, The Netherlands

Roland Becker, MD Prof. Department of Orthopedics and Traumatology,
University Hospital Brandenburg, Brandenburg, Germany

Roman Brzóska, MD, PhD Department of Orthopaedics,
St Luke's Hospital, Bielsko-Biała, Poland

Eduard Buess, MD Shouldercare, Berne, Switzerland

Bernard Burgesson, BSc Queen Elizabeth II Health Sciences Center
Halifax Infirmery, Dalhousie University, Halifax, Canada

James Calder Fortius Clinic & Imperial College, London, UK

O. Chan BMI London Independent Hospital, London, UK

A. Cheli, MD Orthopaedic-Traumatologic Department,
New Sassuolo Hospital, Sassuolo, Italy

Nikica Darabos, MD, PhD General, Orthopaedic and Traumatology
Surgeon, Department of Sports Traumatology,
Clinic for Traumatology, Clinical Hospital Center Sisters of Charity
Medical School, University of Zagreb, Zagreb, Croatia

Pieter d'Hooghe Department of Orthopaedic Surgery,
Aspetar Sportsmedical and Orthopaedic Hospital- FIFA Medical Centre
of Excellence, Doha, Qatar

Peter de Leeuw Department of Orthopaedic Surgery,
Orthopaedic Research Center, Amsterdam, The Netherlands

A. Mehmet Demirtaş, MD Hand & Upper extremity,
Orthopaedic Surgery & Traumatology, Memorial International Hospital,
University Faculty of Medicine, Ankara, Turkey

Julien Deranlot, MD Clinique Drouot, Paris, France

Michael Dienst, MD, PhD OCM München, Munich, Germany

Carl Dierickx Associatie Orthopedie Hasselt, Hasselt, Belgium

C.W. DiGiovanni Department of Foot and Ankle Surgery,
Massachusetts General Hospital, Boston, MA, USA

Pablo E. Gelber, MD, PhD Orthopaedic Surgery,
Hospital de la Santa Creu i Sant Pau, Universitat Autònoma de Barcelona,
Barcelona, Spain

Lars Engebretsen Medical & Scientific Department,
International Olympic Committee, Lausanne, Switzerland
Oslo Sports Trauma Research Center, Norwegian School of Sport Sciences,
Oslo, Norway

Department of Orthopaedic Surgery, Oslo University Hospital and Faculty
of Medicine, University of Oslo, Oslo, Norway

Karl Eriksson Stockholm South Hospital, Karolinska Institutet,
Stockholm, Sweden

Denise Eygendaal, MD, PhD Amphia hospital Breda and University
of Amsterdam, Breda, The Netherlands

Julian A. Feller OrthoSport Victoria, Epworth HealthCare,
Melbourne, Australia

Matthias J. Feucht Department of Orthopedic Surgery and Traumatology,
Freiburg University Hospital, Freiburg, Germany

Giuseppe Filardo Biomechanics Laboratory – II Clinic,
Rizzoli Orthopaedic Institute, Bologna, Italy

Chiara Fossati Università degli Studi di Milano, IRCCS Policlinico
San Donato, Milan, Italy

Brett A. Fritsch, MBBS Sydney Orthopaedic Research Institute, Royal
Prince Alfred Hospital, Mater Private Hospital, North Shore Knee Clinic,
Chatswood, Australia

Karl-Heinz Frosch Department of Trauma and Reconstructive Surgery
with Division of Knee and Shoulder Surgery, Sports Traumatology,
Asklepios Clinic St. Georg, Hamburg, Germany

Christian Gerhardt Center for Musculoskeletal Surgery,
Charité – University Medicine Berlin, Berlin, Germany

Mark Glazebrook, MSc, PhD, MD, FRCSC Queen Elizabeth II
Health Sciences Center, Halifax, NS, Canada

Alli Gokeler, PhD Center of Human Movement Sciences,
University of Groningen, University Medical Center, Groningen,
The Netherlands

S. Gomes Clinica do Dragao Espregueira Mendes Sports Centre – FIFA
Medical Centre of Excellence, Porto, Portugal

Nicolas Graveleau CCOS de la clinique du sport de Bordeaux Mérignac,
Mérignac, France

Stephane Guillo, MD Sport Clinic of Bordeaux Merignac, Mérignac,
France

Daniel Haverkamp SCORE (Slotervaart Center of Orthopedic
Research and Education), Amsterdam, The Netherlands

Philipp R. Heuberger St. Vincent Shoulder & Sports Clinic,
Vienna, Austria

Anna Hirschmann, MD Clinic of Radiology and Nuclear Medicine,
University of Basel Hospital, Basel, Switzerland

Michael T. Hirschmann, MD, PhD Department of Orthopaedic Surgery
and Traumatology, Kantonsspital Baselland (Bruderholz, Liestal, Laufen),
Bruderholz, Switzerland

Saenz Ivan, MD Orthopaedic Surgery, Fundació Hospitalaria de Mollet,
Universitat de Barcelona, Barcelona, Spain

Anne Karelse University of Gent, Gent, Belgium

John G. Kennedy Department of Foot and Ankle Surgery,
Hospital for Special Surgery, New York, NY, USA

Gino M.M.J. Kerkhoffs Department of Orthopaedic Surgery,
Academic Medical Center, Amsterdam, The Netherlands

Maximilian Kerschbaum Center for Musculoskeletal Surgery,
Charité – University Medicine Berlin, Berlin, Germany

Elizaveta Kon Biomechanics Laboratory – II Clinic,
Rizzoli Orthopaedic Institute, Bologna, Italy

Sebastian Kopf, MD Center for Musculoskeletal Surgery,
Charité – University Medicine Berlin, Berlin, Germany

Nanne Kort, MD, PhD Department of Orthopaedic Surgery, Zuyderland
Medical Center location Sittard-Geleen, Sittard-Geleen, The Netherlands

Akos Kynsburg Landesklinikum Scheibbs – Traumatology,
Sports Medicine, Podiatry, Scheibbs, Austria

Karsten Labs, MD, PhD Asklepios Clinic Birkenwerder,
Birkenwerder, Germany

Christoph Lampert Orthopedic Rosenberg, St. Gallen, Switzerland

Robert F. LaPrade, MD, PhD Steadman Philippon Research Institute, Bio
Medical Engineering, Vail, CO, USA

Jonathon Lavelle, MBBS, FRCS Fortius Clinic, London, UK

Umile Giuseppe Longo, MD, MSc, PhD Department of Trauma and
Orthopaedic Surgery, University Campus Bio-Medico of Rome,
Roma, Italy

Emilio Lopez-Vidriero International Sports Medicine Clinic
and Ibermutuamur Sevilla, Sevilla, Spain

Rosa Lopez-Vidriero International Sports Medicine Clinic and
Ibermutuamur Sevilla, Sevilla, Spain

Bent Lund Hospitalsenheden Horsens, Horsens, Denmark

Henning Madry Center of Experimental Orthopaedics,
Saarland University, Homburg, Germany

Nicola Maffulli Queen Mary University of London Barts
and The London School of Medicine, London, UK

Laura Mangiavini Department of Biomedical Sciences for Health,
University of Milan, Milan, Italy, IRCCS Istituto Ortopedico Galeazzi,
Milan, Italy

Fabrizio Margheritini, MD University of Rome “Foro Italico”,
Rome, Italy

Antongiulio Marmotti Department of Orthopaedics and Traumatology,
University of Torino, Torino, Italy

Frank Martetschläger, MD, PhD German Center for Shoulder Surgery,
ATOS Clinic, Munich, Germany

Kentaro Matsui, MD, PhD Dalhousie University, Halifax, Canada

Silvia Mattia Molecular Biotechnology Center, University of Torino,
Turin, Italy

C. Myers Sports Medicine Ultrasound Group, London, UK

Giuseppe Milano, MD Department of Orthopaedics, Catholic University,
Rome, Italy

Service of Shoulder Surgery, “A. Gemelli” University Hospital, Rome, Italy

Håvard Moksnes Oslo Sports Trauma Research Center,
Norwegian School of Sport Sciences, Oslo, Norway

Joan C. Monllau, MD, PhD Hospital del Mar, Hospital Universitari Dexeus,
Universitat Autònoma de Barcelona, Barcelona, Spain

Philipp Moroder, MD Department of Traumatology and Sports Injuries,
Paracelsus Medical University, Salzburg, Austria

Chris D. Murawski Department of Foot and Ankle Surgery,
Hospital for Special Surgery, New York, NY, USA

Wolfgang Nebelung, MD, PhD Marienkrankenhaus
Düsseldorf- Kaiserswerth, Düsseldorf, Germany

Tahir Ogut Department of Orthopaedics & Traumatoloji,
Cerrahpasha Medical School, Istanbul, Turkey

Luke Oh Massachusetts General Hospital, USA

Sakari Orava Department of Orthopaedics, Hospital NEO, Turku, Finland

Mickey Dalmau Pastor Department of Embriology and Human Anatomy,
Universitat de Barcelona, Campus de Bellvitge, Barcelona, Spain

Leo Pauzenberger St. Vincent Shoulder & Sports Clinic, Vienna, Austria

Luigi A. Pederzini, MD Orthopaedic-Traumatologic Department,
New Sassuolo Hospital, Sassuolo, Italy

Fernando Peña, MD Department of Orthopaedic Surgery,
University of Minnesota, Minneapolis, MN, USA

Hélder Pereira, MD PT Government Associated Laboratory, Clínica do
Dragão, Espregueira-Mendes Sports Centre – FIFA Medical Centre of
Excellence, Porto, Portugal

Giuseppe M. Peretti Department of Biomedical Sciences for Health,
University of Milan, Milan, Italy, IRCCS Istituto Ortopedico Galeazzi,
Milan, Italy

Boris Poberaj Department of Surgery, Aspetar Hospital, Doha, Qatar

Nicolas Pujol, MD Department of Orthopedic Surgery and Traumatology,
Versailles Hospital, University of West Paris, rue de Versailles,
Le Chesnay, France

David Putzer Medical University Innsbruck, Innsbruck, Austria

Pietro Randelli, MD Università degli Studi di Milano,
IRCCS Policlinico San Donato, Milan, Italy

Gustaaf Reurink The Sports Physicians Group, OLVG, Amsterdam,
The Netherlands

Maristella F. Saccomanno, MD Department of Orthopaedics,
Catholic University, Rome, Italy

Marc R. Safran, MD Stanford University, Stanford, CA, USA

Hatem Galal Said Assiut, Egypt

Abdou Sbihi, MD Chirurgiens Orthopédistes Et Traumatologues,
Marseille, France

Sven Scheffler, MD, PhD Sporthopaedicum, Berlin, Germany

Markus Scheibel, MD Center for Musculoskeletal Surgery,
Charité – Universitaetsmedizin Berlin, Berlin, Germany

Mitja Scheuermann, MD Center for Musculoskeletal Surgery,
Charité – Universitaetsmedizin Berlin, Berlin, Germany

Ernest Schidlors Professor of Orthopaedic Sports Medicine,
Hip Arthroscopy/Groin Injuries in Sports, Fortius Clinic and Leeds
Beckett University, London, UK

Elvire Servien, MD Hospital de la Croix-Rousse, Centre Albert Trillat,
Lyon University, Lyon, France

Rainer Siebold Center for Hip-Knee-Foot Surgery,
ATOS Clinic and Institute for Anatomy and Cell Biology,
Ruprecht-Karls University, Heidelberg, Germany

Konrad Slynarski LEKMED, Hospital Kartezjusza, Warszawa, Poland

Daniel Smith, MD Mount Sinai Hospital, New York, USA

Wojciech Solecki, MD Department of Orthopaedics, St Luke's Hospital,
Bielsko-Biała, Poland

Francesc Soler ITRT, Centro Médico Teknon, Barcelona, Spain

Christian Stärke, MD, PhD Department of Orthopaedic Surgery,
Otto-von-Guericke University, Magdeburg, Germany

Vladan Stevanovic, MD Orthopaedic Surgeon, Faculty of Medicine,
University of Belgrade, Belgrade, Serbia

Institute for Orthopedic Surgery “Banjica”, Mihajla Avramovica 28,
Belgrade, Serbia

Masato Takao, MD, PhD Department of Orthopaedic Surgery, Teikyo
Institute of Sports Science and Medicine, Teikyo University, Tokyo, Japan

Ettore Taverna, MD Upper Limb Unit, Department of Surgery,
OBV Mendrisio, Mendrisio, Switzerland

U.O. Chirurgia della Spalla II, Istituto Ortopedico Galeazzi, Milan, Italy

Katja Tecklenburg Medalp Sportclinic Imst, Imst, Austria

Marc Tey Hip Unit, Orthopaedics Department, Hospital del
Mar i Esperança, Barcelona, Spain

Johannes L. Tol Amsterdam Center of Evidence Based Sports Medicine,
Academic Medical Center, Amsterdam, The Netherlands

Bruno Toussaint, MD Clinique Generale, Annecy, France

E. Tripoli, MD Orthopaedic-Traumatologic Department,
New Sassuolo Hospital, Sassuolo, Italy

Dieter Van Assche Division of Rheumatology,
University Hospitals Leuven, Leuven, Belgium

Michel P.J. van den Bekerom Department of Orthopedic Surgery,
Onze Lieve Vrouwe Gasthuis, HM Amsterdam, the Netherlands

Anne D. van der Made Aspetar, Qatar Orthopaedic and Sports Medicine
Hospital, Doha, Qatar

Pim A.D. van Dijk Department of Orthopedic Surgery,
Academic Medical Center, Amsterdam, The Netherlands

Roger P. van Riet, MD, PhD University Hospital Antwerp, Antwerp,
Belgium

A. Van Tongel, MD, PhD University Hospital, Ghent, Belgium

Jordi Vega, MD Foot and Ankle Unit, Hospital Quirón, Barcelona, Spain

Mihai Vioreanu, MD, MCh, FRCSI (Tr&Orth) Consultant Orthopaedic
Surgeon, Knee and Hip Specialist, Sports Surgery Clinic, Santry, Dublin 9,
Ireland

Andy Williams, MBBS, FRCS (Orth), FFSEM (UK) Fortius Clinic,
London, UK

Erik Witvrouw Aspetar, Qatar Orthopaedic and Sports Medicine Hospital,
Doha, Qatar

Department of Rehabilitation and Physiotherapy, Faculty of Medicine
and Health Science, Gent University, Belgium

Pelfort Xavier, MD, PhD Orthopaedic and Trauma Department – Consorci
Sanitari de l’Anoia – Hospital d’Igualada, ICATME – Hospital Universitari
Quirón Dexeus, Barcelona, Spain

Youichi Yasui Department of Orthopaedic Surgery, Teikyo University
School of Medicine, Tokyo, Japan

Urzula Zdanowicz, MD Carolina Medical Center, Warsaw, Poland

Oskar Zupanc, MD, PhD Orthopaedic Surgeon, Department
of Orthopaedic Surgery, Ljubljana University Medical Centre, Ljubljana,
Slovenia

Management of PCL Injuries (ICL 1)

1

Fabrizio Margheritini, Robert La Prade,
and Sven Scheffler

The posterior cruciate ligament (PCL) is the primary stabilizer of the knee joint and is the major restraint to posterior tibial translation. PCL insufficiency after the ligament's rupture modifies the knee kinematics and may result in functional limitations in sports and daily activities. The management of PCL injuries remains a matter of debate, largely due to the lack of prospective studies delineating the true natural history of the injury and the absence of randomized trials comparing the outcomes of current modes of treatment.

1.1 Anatomy and Biomechanics of the Posterior Cruciate Ligament

Fabrizio Margheritini

Understanding the anatomy and biomechanics of the PCL is important to diagnosing and treating its injury. This ligament is a complex structure that arises from the posterior tibia 1 cm below the joint line and extends anteromedially to the lateral surface of the medial femoral condyle. The PCL averages in length between 32 and 38 mm and has a cross-sectional area of 31.2 mm² at its midsubstance level, which is 1.5 times that of the anterior cruciate ligament (ACL) cross-sectional area. Its femoral (Fig. 1.1) and tibial insertion sites are approximately three times larger than the cross-sectional area at the midsubstance level of the ligament. The large ligamentous insertion sites and the lack of isometry within the fibers of the PCL complicate the task of designing a PCL reconstruction technique that adequately recreates the anatomical and biomechanical properties of the intact PCL. The ligament consists of two functional components referred to as the anterolateral (AL) and the posteromedial (PM) bundles. The AL bundle is two times larger in cross-sectional area than the PM bundle and they behave differently depending on the degree of knee flexion. During passive flexion and extension of the knee, the anterolateral bundle is more

F. Margheritini, MD (✉)
University of Rome "Foro Italico", Rome, Italy
e-mail: mararthro@gmail.com

R. La Prade, MD, PhD
Steadman Philippon Research Institute, Bio Medical
Engineering, Vail, CO, USA

S. Scheffler, MD, PhD
Sporthopaedicum,
Bismarckstrasse 45-47, Berlin 10627, Germany
e-mail: sven.scheffler@gmx.com

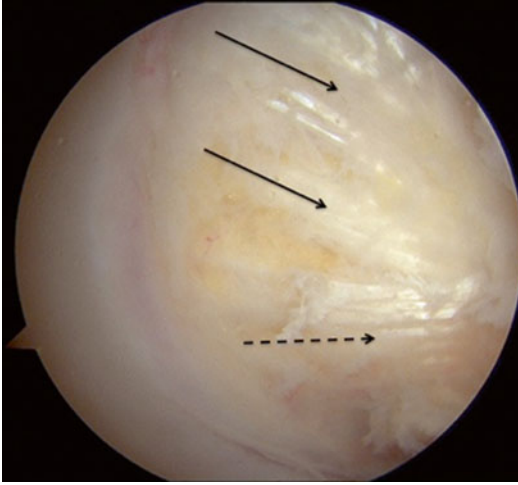


Fig. 1.1 Arthroscopic view of the femoral insertion of the PCL (*continuous black line*) and the anterior meniscofemoral ligament (*dotted line*)

taught in flexion and lax in extension. Conversely, the posteromedial bundle is more taught in extension and lax in flexion. Despite the widespread acceptance of this anatomical division of the PCL, alternate anatomic descriptions of the PCL exist, including three- and four-bundle divisions as well as a continuum of PCL fiber orientation. In addition to the anterolateral and posteromedial bundles, there are two meniscofemoral ligaments (MFL) closely associated with the PCL: the ligament of Humphrey (anterior) and the ligament of Wrisberg (posterior). They originate from the posterior horn of the lateral meniscus, run alongside of the PCL, and insert anterior and posterior to the PCL on the medial femoral condyle. The presence of these ligaments is highly variable and discrepancies exist in the literature regarding their prevalence, but they are believed to be significant anatomic and biomechanical structures that provide stability to the lateral meniscus. Biomechanical studies have shown that the PCL is one of the major stabilizers of the knee. It has a primary function of preventing posterior tibial displacement and a secondary role in limiting external, varus, and valgus rotations. Initial tensile testing reported the tensile strength of the excised PCL to be twice that of the ACL. Studies showed the linear stiffness of the anterolateral bundle (120 ± 37 N/m) to be 2.1 times that of the

posteromedial bundle and 2.5 times that of the MFL, and the ultimate load of the anterolateral bundle ($1,120 \pm 362$ N/m) to be 2.7 times that of the posteromedial bundle and 3.8 times that of the MFL. Several biomechanical cutting studies have demonstrated that isolated section of the PCL increases posterior tibial translation progressively as the knee is flexed from 0 to 90°, with maximal increase in translation occurring at 90° of knee flexion. Furthermore, results suggest that a biomechanical interaction exists between the PCL and the posterolateral structures (PLS) in providing stability to the knee. Isolated sectioning of the PCL results in posterior tibial translation by up to 11.4 ± 1.9 mm, while isolated sectioning of the PLS increases posterior translation between 1.5 and 4 mm. However, after sectioning of both the PCL and PLS, posterior tibial translation in response to a posterior load is increased by up to 25 mm. Combined PCL and PLS section increases posterior tibial translation at all degrees of knee flexion greater than isolated PCL section. The PLS is a secondary restraint to posterior tibial translation, contributing to posterior stability particularly in the PCL-deficient knee, while it plays a primary role in resisting excessive varus and external rotational forces. Isolated section of the PLS increases varus and external rotations maximally at 30–45° and has little effect on these rotations at 90° of knee flexion. Combined PCL and PLS section increases varus and external rotations at both 30 and 90°. These findings, in addition to the results pertaining to posterior tibial translation, suggest a synergistic relationship between the PCL and the PLS in providing stability to the knee.

1.2 Evaluation and Indications for PCL Surgery

Sven Scheffler

1.2.1 Evaluation

Evaluation for injuries of the PCL starts with analysis of patient history. The patient should be asked

about existing knee complaints, whether it is pain or instability or a combination of both. In chronic cases of PCL injury, patients often complain about anterior knee pain due to the posterior subluxation of the tibia, especially when a sitting position is maintained for a longer period of time. Sensations of instability are less frequently reported unless combined PCL insufficiency exists. In acute cases of PCL injury, patients are mainly compromised in their knee function due to swelling and pain with instability becoming more relevant after the loss of effusion. It must be evaluated what type of knee trauma occurred. Typical for PCL injuries is a direct trauma to the proximal tibia with the knee in flexion. However, hyperextension trauma of the knee can also result in PCL rupture.

During clinical examination patients should lay in supine position. In acute injuries, general inspection of the knee joint should check for pre-tibial signs of injury and hematoma in the back of the knee. Typically an effusion can be found, which often limits range of motion. With the knee in 90° of flexion and the foot stabilized by the examiner, the anterior tibial rim is palpated, which should be in front of the femur, which is called the *tibial step-off* (Fig. 1.2). When the tibia is pushed posteriorly, the tibial rim must remain anterior to the femur with an intact PCL. If the tibia can be pushed under or even posterior to the femoral condyles, PCL injury is imminent (*positive posterior drawer sign*). Often PCL injury is mistaken for an ACL injury in clinical examination due to a posteriorly subluxed tibia at the starting position

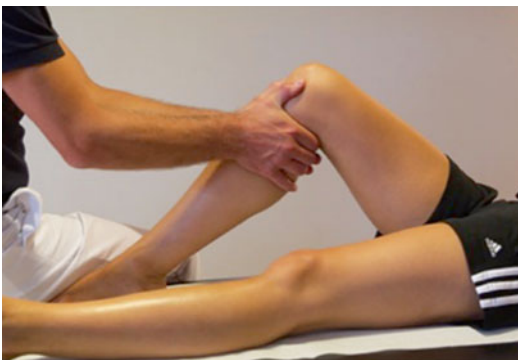

Fig. 1.2 Posterior drawer test with palpation of the tibial step-off

of the anterior-posterior drawer test. Therefore, it is important to first pull the tibia anteriorly until the tibial step-off is palpable before executing the posterior drawer test. Always, clinical test must be examined on the injured and intact contralateral knee to differentiate insufficiency from inherent individual laxity.

In chronic PCL deficiency, a posterior sag of the tibia can be observed at 90° of flexion compared to the intact contralateral knee. Also, a posterior subluxation of the tibia can be provoked by the patient when trying to actively extend the knee flexed at 60° and the foot fixed to the examination table (*quadriceps pull test*).

PCL lesions are often combined with injuries to the posterolateral corner, to a lesser extent to the medial structures of the knee joint. First the lateral collateral ligament (LCL) is examined in extension and 30° of flexion by lateral opening of the knee joint (*varus stress test*). Opening only at 30° is associated with isolated LCL injury, while additional opening at extension is suggestive of injury to the posterolateral corner (e.g., arcuate complex) of the knee joint. Injury to the posterolateral structures, such as the popliteus tendon and arcuate complex, results into substantially increased posterior instability, but especially to external rotational instability. This can be evaluated at the 90° flexed knee by rotating the tibia externally while fixing the foot to the examination table and repeating the same test on the contralateral knee. The *dial test* is another clinical technique to analyze rotational instability, especially in combined injuries with the PCL. The patient lies in prone position and an assistant gently stabilizes both knee joints, while the examiner holds both feet of the patient and rotates them externally. The test is performed at 30° and 90° of flexion. If increased external rotation is noticed at 30° and 90° of flexion, combined injury to the PCL and posterolateral structures is probable.

Anterolateral structures are examined in 20° of flexion with increased opening anteriorly compared to the healthy contralateral side. Also, increased internal rotation in 20° and 90° of flexion might be suggestive of such injury. Medial structures are analyzed by valgus opening (*valgus stress test*) at extension and 30° of flexion.

Increased opening at 0° and 30° of flexion is suggestive of injury to the medial collateral ligament and the posterior oblique ligament, which in most cases requires surgical intervention. Isolated opening at 30° of flexion is caused by injury of the superficial medial collateral ligament, which can heal successfully with conservative treatment.

If acute PCL injury is assumed, conventional x-rays of the knee joint (AP and lateral) are taken to exclude fractures of the tibia and femur. Sometimes, a posterior sag of the tibia relative to the femur can be observed. If PCL injury is suspected and no substantial swelling is present, the patient should be examined under dynamic fluoroscopy on both knee joints for anterior and posterior translation in 90° flexion. If swelling has already occurred, pain will prevent precise examination with the patient awake. If the patient will have to undergo immediate surgery due to related injuries, this examination should be performed in the operation room prior to surgery. Immediate magnetic resonance imaging (MRI) of the knee joint should be carried out, which is highly sensitive and specific for injury of the PCL and intra-

and extra-articular peripheral structure periphery. This is of importance to differentiate between a single-ligament and multiligament injury.

Since PCL injury often requires a substantial trauma to the knee joint and associated injuries are frequent, vascular injuries must be excluded. Doppler ultrasound examinations should be performed at the time of injury and repeated at 24 and 48 h to exclude intima lesions that often present with timely delay.

Stress x-rays are not indicated in the acute setting. Swelling and pain will stop patients from relaxing the hamstrings, which prevents valid measurements of true anterior-posterior translation.

In chronic PCL insufficiency, it is detrimental to quantify the extent of posterior instability, especially when differentiating isolated from combined chronic injuries. Objective quantification and comparison of posterior translation of the tibia relative to the femur between both knee joints are of crucial importance. Conventional stress x-rays allow such analysis on exact lateral views with different imaging methods being described, such as Telos (Fig. 1.3) or kneeling

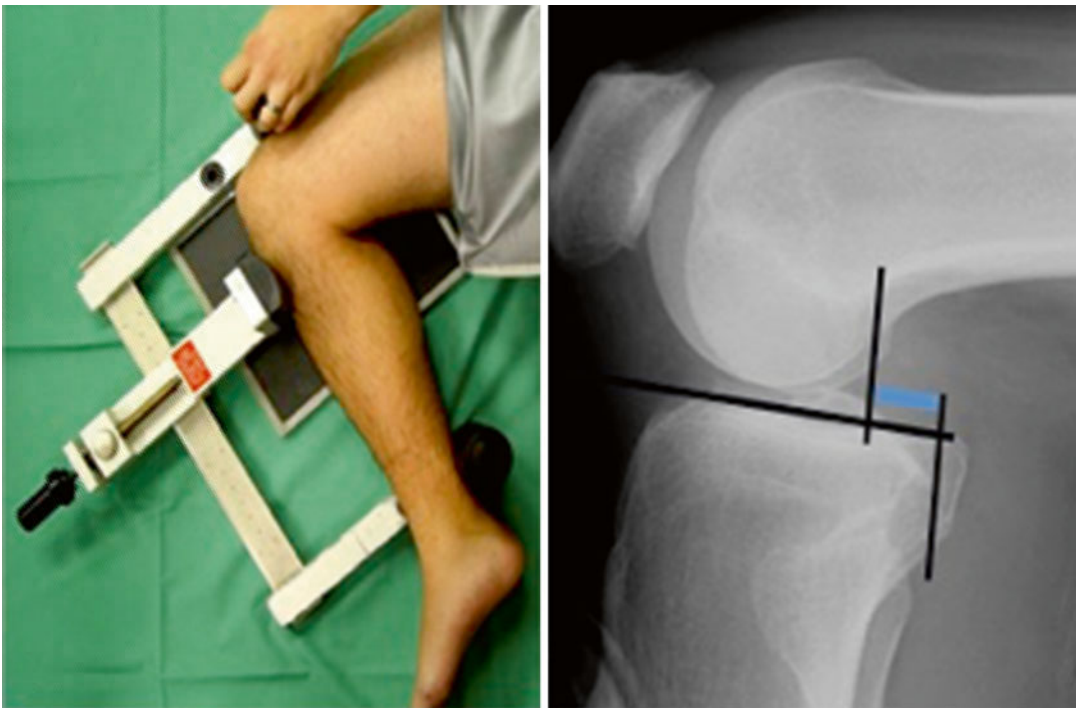


Fig. 1.3 Telos stress x-ray for quantification of posterior translation

technique. It has been shown that side-to-side differences (SSD) of 12 mm or more between the injured and intact knee are highly suggestive of combined PCL injuries, while differences of less than 10 mm are an indicator for isolated chronic PCL insufficiency [1]. Another important phenomenon is the so-called fixed posterior subluxation [2]. It results from permanent posterior tibial subluxation without the possibility of fully restoring anterior-posterior translation in patients with chronic PCL insufficiency. It is of utter importance to exclude such fixed posterior subluxation prior to PCL surgery by conducting stress x-rays in anterior and posterior drawer position on both knee joints. A difference in SSD of 3 mm or more in reduced anterior translation of the PCL-deficient knee is indicative of fixed posterior subluxation on anterior stress x-rays. Such quantification has only been shown until now using Telos technique [2]. If a fixed posterior subluxation is found on anterior stress x-rays, full restoration of anterior-posterior translation must be achieved prior to PCL surgery.

MRI analysis of chronic PCL insufficiency has limited use, since the PCL can recover normal signal intensity during healing independently from its true functional recover. Therefore, MRI imaging has its main use to visualize concomitant injuries, especially to the cartilage of the patellofemoral and medial joint compartment, which are often associated with long-lasting PCL deficiency.

1.2.2 Indications for PCL Surgery

Acute isolated injury of the PCL can be treated successfully with conservative therapy by immobilization of the injured knee in a tibial repositioning knee brace for a time period of 6 weeks. With chronic isolated PCL insufficiency, it is essential to confirm that no combined instability of the peripheral structures of the knee joint exists. If patients complain about clinical symptoms, such as patellofemoral pain and/or subjective instability and clinical examination and radiographic analysis with stress x-rays verify isolated injury of the PCL, a brace test with a

tibial repositioning brace should be executed for 3–6 weeks. If clinical symptoms subside, isolated PCL reconstruction should be recommended [3].

Acute combined injuries of the PCL and the medial/lateral periphery of the knee joint often result in permanent knee instability [4]. Therefore, reconstruction of the PCL and its comorbidities is recommended [4]. Most often, PCL rupture is associated with injuries of the posterolateral structures, such as the arcuate complex, the popliteus tendon, and the lateral collateral ligament. The excess of posterolateral injury must be assessed during clinical examination, while MRI will confirm the full extent of injury as long as it is conducted shortly after trauma. It is recommended to reconstruct all impaired structures in a single-time procedure. This avoids overloading of the PCL reconstruction and premature failure due to non-addressed peripheral instability [5]. Less often, PCL rupture is combined with injuries of the medial structures of the knee joint. Identical approach should be taken to restore medial side knee stability at the same time when performing PCL reconstruction [6]. In multiligament injuries of the ACL, PCL, and the periphery, ideally, single-staged reconstruction of all ligaments should be undertaken. It has been shown that suturing of the impaired structures, even in the acute setting, results in increased rates of insufficiency compared to augmentation/reconstruction [7]. If the general condition of the knee joint will not allow for prolonged surgical time, staged reconstruction can be opted for. First, reconstruction of the central ligaments (ACL, PCL) should be performed, while addressing all peripheral structures as soon as the overall knee condition permits further surgical intervention.

In combined chronic PCL insufficiency, reconstruction of all impaired structures is required. It is of fundamental importance to exclude a fixed posterior dislocation of the tibia prior to PCL reconstruction [2] to avoid stabilization of the knee joint in a subluxed position. Surgical reconstruction of all structures should be carried out in a single-staged procedure to prevent excessive loading of the respective structures due to persisting, even partial, instability.

1.3 Surgical Treatment: Arthroscopic vs Inlay

Fabrizio Margheritini

PCL reconstruction techniques can be categorized as arthroscopic (transtibial) or open (inlay). Furthermore, the type of PCL reconstruction can be described as a single- or double-bundle technique, according to the graft construct that is chosen for the reconstruction.

1.3.1 Transtibial Tunnel Technique

The transtibial technique has been popularized by Clancy et al. in 1983 [8]. It is based on the use of a single tibial tunnel that is drilled from the anteromedial aspect of the proximal tibia to the posterior aspect of the proximal tibia at the site of PCL insertion. Even though it was originally described as an open procedure, the technique is now routinely performed arthroscopically.

Following an exam under anesthesia, the patient is positioned using well-padded leg holders, and the tourniquet is placed on the proximal thigh of the injured leg but not inflated during the procedure in order to better control the intraoperative bleeding. Anatomic landmarks are delineated on the skin with a marking pen. Standard anteromedial and anterolateral portals are established on the joint line adjacent to the borders of the patellar tendon. Diagnostic arthroscopy is performed to assess all intra-articular structures and address the torn ligament and associated pathology. Author's preferred method at this point establishes a posteromedial and posterolateral accesses and a transeptal approach is prepared. Even if the transeptal portal is not mandatory for performing a transtibial reconstruction, removing the posterior septum allows a better visualization of the posterior compartment keeping away from the working area the popliteal artery (Fig. 1.4).

Tibial tunnel is drilled using a PCL guide set between 50 and 55° and introduced through the anteromedial portal under direct visualization. The scope can be placed either via posteromedial or posterolateral access allowing an optimal

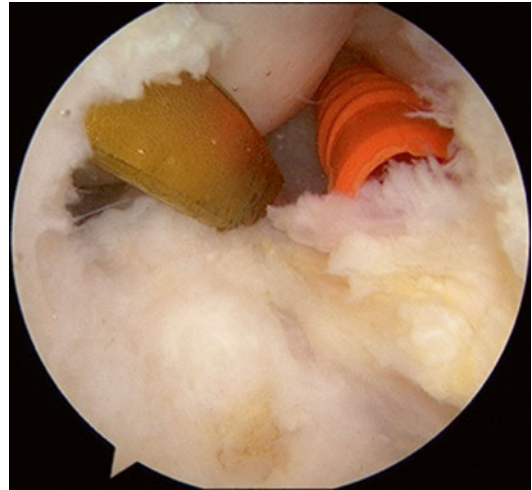

Fig. 1.4 Arthroscopic view of the transeptal approach. Scope is through posterolateral portal controlling the tibial guide placement. The cannula in the posteromedial portal allows using any additional tool to help this step

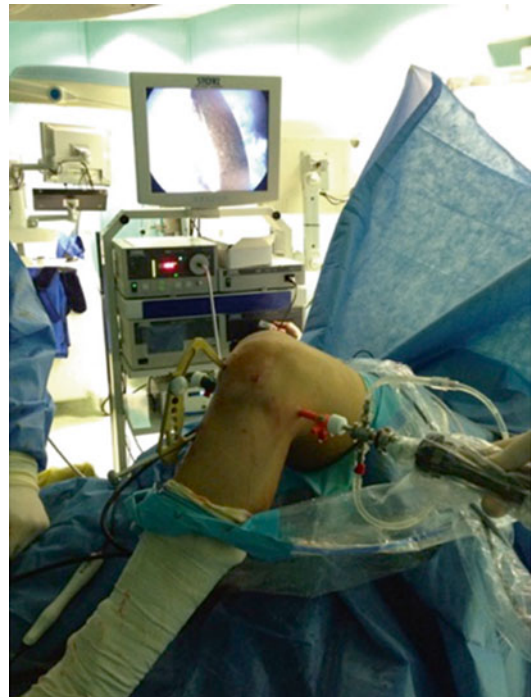

Fig. 1.5 External view of the tibial tunnel preparation by using the transeptal approach. The scope is introduced through the posterolateral portal, while the tibial guides (visible on the screen) through the anteromedial portal

visualization of the posterior area (Fig. 1.5). Care is taken in order to position the tibial tunnel exit within the area of AL bundle attachment in order

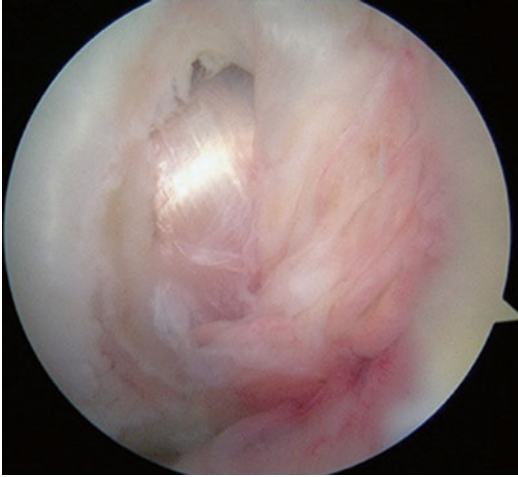

Fig. 1.6 Arthroscopic final view of the femoral PCL tunnel, with graft already fixed. Note the high position of the graft, resembling the AL bundle, with preservation of both the Humphrey's ligament and the PM bundle

to preserve the highest number possible of PM fibers. Then placing the scope through the antero-lateral access, the PCL femoral stump is debrided and the femoral tunnel can be drilled either using an outside-in or inside-out technique. Here, great care should be used to preserve the posteromedial (PM) bundle and the menisiofemoral ligament insertion (Fig. 1.6). The graft is pulled through the tibial tunnel, over the posterior aspect of the tibial plateau, and into the femoral tunnel using a looped 18-gauge wire or graft passer.

A blunt trocar introduced through the PM portal can be helpful in assisting the progression of the graft. When using a graft with a bone block, it is advisable to keep it on the tibial tunnel, where the bone density is considerably less than in the femoral tunnel, allowing a stronger fixation and a faster healing process.

Before final fixation, the graft should be preconditioned to minimize elongation; this is accomplished by passively moving the knee through its full range of motion several times while applying tension (10 lb) to the unfixed end of the graft. During fixation of the AL graft (for both the single- and double-bundle techniques), the knee is held in 70–90° of flexion, and an anterior drawer force is applied to recover the normal step-off between the medial femoral condyle and the medial tibial plateau.

1.3.2 Inlay Technique

The inlay technique for PCL reconstruction was first described in Europe by Thomann and Gaechter in 1994 [9] and later popularized in the USA. This technique originally designed to provide anatomic reconstruction of the AL can reproduce the two ligament bundles of the PCL by splitting one tail of the graft.

The technique requires an open posterior approach to the knee, which allows the direct fixation of a bone plug graft complex (patella tendon, Achilles tendon) to a unicortical bone trough at the anatomic site of tibial PCL insertion. This fixation, theoretically, should avoid the sharp angle of the graft observed at the proximal margin of tibial tunnel in the more traditional trans-tibial technique.

For the inlay technique, the patient is either positioned in the lateral decubitus position (injured leg up) for the entire procedure or requires intraoperative repositioning from a supine to a prone position. These two options for positioning allow access to the anterior and posterior aspects of the knee. In the lateral decubitus position, the hip is abducted and externally rotated, and the knee is flexed to 90° during anterior arthroscopy, graft harvest, and arthroscopic drilling of the femoral tunnel. Following anterior arthroscopy, the knee must be fully extended and slightly abducted to achieve adequate exposure for the posterior approach. If anterior arthroscopy is performed while the patient is supine, the patient must be turned prone intraoperatively to achieve adequate exposure for the posterior approach to the knee. Femoral tunnel is drilled during anterior arthroscopy as described above. A looped 18-gauge wire or graft passer, that is later used to pass the graft, is then placed through the femoral tunnel into the joint. The injured leg of the patient is then repositioned in preparation for the posterior approach.

The posterior approach used in the tibial inlay technique involves an oblique incision lateral to the medial gastrocnemius muscle as described by Burks and Schaffer [10]. The deep fascia of the medial gastrocnemius muscle is incised vertically, parallel to the direction of the muscle fibers. Attention must be paid to the sural nerve, which

runs between the medial head of the gastrocnemius muscle and the semimembranosus tendon.

The head of the medial gastrocnemius muscle is incised and retracted laterally along with the neurovascular structures of the popliteal region. A vertical incision is made in the posterior capsule to expose the site of tibial PCL insertion. A unicortical bone block is removed at the tibial PCL insertion site to create a trough that will accommodate the bone plug of the graft. The bone plug of the graft is placed in the trough and fixed with a 6.5-mm cancellous screw and washer. Using the Ethibond sutures attached to the tendinous end of the graft and the prepositioned looped 18-gauge wire, the graft is passed through the femoral tunnel and fixed.

It remains unclear whether the anatomic fixation of the PCL graft achieved by the inlay technique is more efficacious than the traditional transtibial technique in restoring normal knee biomechanics. Either biomechanical or clinical studies have failed to show significant difference in knee stability when comparing the two surgical techniques. More recently in order to combine the effectiveness of an arthroscopic procedure with the advantage of a direct fixation, a full arthroscopic inlay procedure has been described addressing both the tibial side and the femoral side by Margheritini and Mariani [11, 12]. This technique involves the fixation of the bone block either on the tibial or femoral side by using a full arthroscopic technique. The bone block is placed in the desired position after preparing an adequate slot and fixed by using transosseous suture on a metallic button placed on the medial femoral condyle/anterior tibial border. Despite the enthusiastic early reports, mid- and long-term clinical studies are lacking, restricting the use of this technique to selected cases.

1.4 Conservative Treatment of PCL Injuries

Robert La Prade

The PCL has been reported to have intrinsic healing ability. As a result, acute, isolated PCL tears

can often be successfully treated with nonoperative management. A biomechanical study by Kennedy et al. [13] demonstrated that isolated PCL injuries that involve a tear to only one of the bundles result in minimally increased posterior tibial translation (<3 mm) throughout range of motion. This may explain why acute partial tears have a good prognosis with nonoperative management. However, PCL tears that are chronic or involve concomitant ligament injuries to the effected knee have been reported to have improved outcomes with operative management. Posterior stress radiographs are essential to objectively aid in the diagnosis of PCL injury and can be used to distinguish between partial, complete, and associated multiligament injuries. With the use of a standardized posterior force, posterior stress radiographs have repeatedly demonstrated reliable reproduction and objective assessment of posterior tibial translation. Recently, the use of a brace that applies a constant or dynamic anterior force to the posterior proximal tibia has been advocated for treatment of isolated PCL injuries [14].

1.4.1 Conservative Treatment

Studies have reported a range of outcomes with nonoperative management of PCL tears. However, a recent review by LaPrade et al. [5] reported a consistent finding across studies to be that PCL tears with associated ligament injuries resulted in worse outcomes when treated nonoperatively. Torg et al. [15] reported that isolated PCL tears treated conservatively had favorable outcomes at a mean 5.7-year follow-up. The same study reported on nonoperative treatment of PCL tears with concurrent ligament injury and found significantly higher incidences of osteoarthritic progression and fair or poor functional outcomes. Other studies on isolated acute PCL tears treated conservatively reported a healed appearance of the PCL on magnetic resonance imaging (MRI) at 1.7 and 2.6 years after the injury; however, subjective outcome scores in both studies were less than satisfactory. Authors concluded that this discrepancy

between imaging and subjective outcomes was the result of attenuated healing of the PCL. Patel et al. [16] and Shelbourne et al. [17] followed patients with isolated PCL tears treated conservatively and reported radiographic evidence of arthritic changes in 23 % of patients at 7-year follow-up and 41 % at 14-year follow-up, respectively. Of note, only 11 % of patients in the study by Shelbourne et al. had moderate to severe OA, and the majority had full range of motion, good subjective outcome scores, and strength that was nearly equal (97 %) to the uninjured leg.

Braces that apply an anteriorly directed force to the proximal tibia have been proposed to support PCL healing by reducing the tibia to its anatomical location, thereby minimizing PCL elongation. Jacobi et al. [18] reported on a static anterior drawer brace (PCL-Jack brace, Albrecht GmbH, Stephanskirchen, Germany) used for 4 months in patients with isolated acute PCL tears. At 6 months after the injury, the investigators reported restoration of PCL continuity in 95 % of patients based on MRI and significantly reduced posterior tibial sag from initial clinic visit (7.1 mm) to follow-up at 12 and 24 months (2.3 and 3.2 mm, respectively). However, decreases in Lysholm scores reported at 12 and 24 months were clinically insignificant. A study by Janson et al. [19] on PCL bracing recommended that to best support the PCL-deficient knee, braces should apply dynamic forces to the knee joint that replicate the anatomic forces applied by the native PCL. It has been documented that these forces are dependent on the degree of knee flexion, and the maximal force and elongation occurring between 90 and 120°, and decreasing with extension. As a result, LaPrade et al. [14] compared the use of a static (PCL-Jack brace, Albrecht GmbH, Stephanskirchen, Germany) versus a dynamic (Rebound PCL, Össur Inc., Foothill Ranch, CA, USA) anterior drawer brace for the treatment of isolated acute PCL injuries. They reported that the dynamic force brace applied significantly larger forces to the proximal posterior tibia at higher flexion angles compared to the static force brace.

1.4.2 Future Treatment Options

PCL bracing has recently gained popularity. However, further clinical studies are necessary to determine long-term outcomes. Specifically, there is a need for high-quality studies of the dynamic force brace to determine whether the loading characteristics of this brace, which more closely replicated the in situ loading profile of the native PCL, will result in long-term improved posterior knee laxity following isolated acute PCL injury.

Finally we can summarize that the PCL has intrinsic healing ability. Conservative treatment is best reserved for acute isolated PCL injuries. The use of an anterior drawer brace to reduce the tibia to its anatomical position may help decrease posterior tibial laxity.

References

- Schulz MS, Steenlage ES, Russe K, Strobel MJ. Distribution of posterior tibial displacement in knees with posterior cruciate ligament tears. *J Bone Joint Surg Am.* 2007;89:332–8. doi:[10.2106/JBJS.C.00834](https://doi.org/10.2106/JBJS.C.00834).
- Strobel MJ, Weiler A, Schulz MS, et al. Fixed posterior subluxation in posterior cruciate ligament-deficient knees: diagnosis and treatment of a new clinical sign. *Am J Sports Med.* 2002;30:32–8.
- Petrigliano FA, McAllister DR. Isolated posterior cruciate ligament injuries of the knee. *Sports Med Arthrosc.* 2006;14:206–12.
- Strobel MJ, Schulz MS, Petersen WJ, Eichhorn HJ. Combined anterior cruciate ligament, posterior cruciate ligament, and posterolateral corner reconstruction with autogenous hamstring grafts in chronic instabilities. *Arthroscopy.* 2006;22:182–92.
- LaPrade CM, Civitarese DM, Rasmussen MT, LaPrade RF. Emerging updates on the posterior cruciate ligament: a review of the current literature. *Am J Sports Med.* 2015. doi:[10.1177/0363546515572770](https://doi.org/10.1177/0363546515572770).
- Fanelli GC, Fanelli DG. Management of chronic combined PCL medial posteromedial instability of the knee. *Sports Med Arthrosc.* 2015;23:96–103.
- Stannard JP, Brown SL, Robinson JT, et al. Reconstruction of the posterolateral corner of the knee. *Arthroscopy.* 2005;21:1051–9.
- Clancy Jr WG, Shelbourne KD, Zoellner GB, Keene JS, Reider B, Rosenberg TD. Treatment of knee joint instability secondary to rupture of the posterior cruciate ligament. Report of a new procedure. *J Bone Joint Surg Am.* 1983;65(3):310–22.